

# Successful skin healing without any graft reconstruction after scalpel blade paring of huge rhinophyma: a case report and review of literature\*

Khalid Mohamed Bofares

Omar Almoukhtar University, Elbyda, Libya

**Rhinology Online, Vol 5:** 133 - 136, 2022

<http://doi.org/10.4193/RHINOL/22.027>

**\*Received for publication:**

August 4, 2022

**Accepted:** September 1, 2022

**Published:** September 19, 2022

## Abstract

Rhinophyma is considered as a benign tumor of the exterior of the nose. It is a disfiguring soft tissue hypertrophy of the nasal skin, predominantly seen in older, white men. It is believed to be the final stage of acne rosacea. The main presentation of the patients with rhinophyma is the cosmetic disfigurement, although it may also cause nasal obstruction and visual disturbance. The rhinophyma is mainly treated by surgical intervention, which exists in different forms, but all will provide almost similar cosmetic results. Our presentation constitutes one case of rhinophyma treated by paring with a sharp scalpel. The case showed satisfied cosmetic results with a complete healing of the raw area without any skin graft reconstruction.

**Key words:** rhinophyma, surgical treatment of rhinophyma

## Introduction

Rhinophyma is a benign disfiguring condition due to hyperplasia of sebaceous glands and fibrous tissue of the skin over the nose. It is the end stage of progression of acne rosacea. It is more commonly seen among older males. The tip of the nose is considered as the most common site that is affected, but it can also affect other sites like the glabellas, malar region and chin. The main reason for patient's medical consultation is cosmetic. A large rhinophyma may cause nasal obstruction and sometimes obscure to vision. Treatment of rhinophyma is mainly surgical, by sharp dissection, electrodesiccation, or laser. Dermabrasion may be useful in final contouring of the nose <sup>(1,2)</sup>.

## Case report

A sixty-five-year-old Libyan male patient presented at the ENT department – AL Thawra central teaching hospital – AL Beyda city – Libya with complaints of swelling over the exterior of the nose. A complete history was taken regarding the onset, duration, and progression of the disease, and for any significant past medical history, such as diabetes mellitus or any other chronic illness, which revealed a non-significant past medical history.

The occupation of the patient, as well as his habitual status regarding smoking and alcoholism were confirmed through a socio-habitual history. The patient was neither smoker nor an alcoholic. He was working as a farmer and sheep keeper with long-standing exposure to sunrays during daytime.

A general and ENT related examination was performed and the diagnosis of rhinophyma was made clinically. The lesion was appearing as lobulated nodular masses raised from the skin over the area of the lower lateral cartilages of both sides of the exterior of the nose with obvious increase of the vascularity of the skin of the lesions as illustrated telangiectasia. The lesion was non-tender by palpation, and it was so large to partially disturb the normal visual function of the patient. Endoscopic examination of the nasal cavity was performed to rule out a co-existent nasal pathology. The patient was counseled regarding the selected treatment manner and informed consent was taken from him regarding the management modality as well as the publication of his taken personal photos.

Dissection of the tumor was performed under general anesthesia using a sharp scalpel. Resected tissue was sent for histopathological examination to rule out the presence of a malignancy.

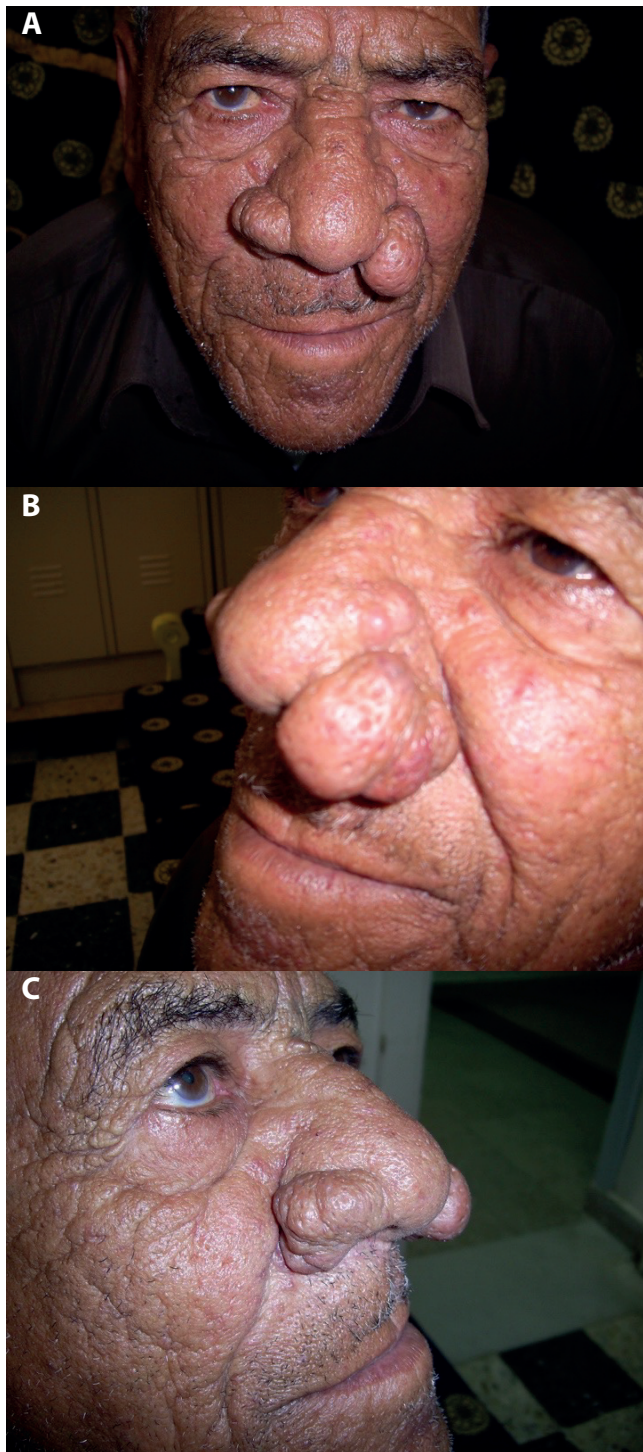


Figure 1. The lesion is shown before surgery. A) frontal view; B) left beside view; C) right beside view

The raw area was left without any skin grafting. A dressing was applied using bismuth – iodine – paraffin paste gauze. Oral antibiotics and analgesics were given post-operatively. The dressing was done daily by the same type of material. The patient was discharged after five days and followed every after day for dressing until complete healing was obtained by two weeks.

Histopathology results of the specimens were confirmatory for rhinophyma. After that, the patient was followed monthly for a further six months to exclude any local recurrences.

### Discussion

Rhinophyma was first recognized in ancient Greece and Arabia. In 1845, Von Hebra coined the word Rhinophyma <sup>(2)</sup>. He derived this word from the Greek word “rhin” meaning nose and “phyma” meaning growth. In 1846, Virchow associated Rhinophyma with acne rosacea <sup>(3)</sup>.

Pathologically speaking, acne rosacea is characterized by telangiectasias, erythema, thickened skin, tuberos nodules, and lobules. Histologically, there will be sebaceous gland hyperplasia, fibrosis, and hypervascularity. Rebora <sup>(4)</sup> described four stages of acne rosacea: the pre-rosacea stage with frequent facial flushing; the vascular rosacea stage with thickened skin, telangiectasias, and erythema; the inflammatory stage where there is erythematous papules and pustules; and the fourth stage is described as rhinophyma.

Rhinophyma is usually limited to the lower third of the nose, but occasionally the chin and forehead can also be involved <sup>(5)</sup>. A similar condition can be seen in the ear pinna, which is called otophyma.

The prevalence of acne rosacea is about 0.5% to 10%. The male: female ratio is about 5:1 to 30:1 as reported by Wiemer <sup>(6)</sup>. Although acne rosacea is seen predominantly in females, with a male: female ratio of 1:3, rhinophyma is seen mainly in men. The increased incidence in men is assumed to be due to androgenic influence. It is mainly seen in Caucasian men <sup>(5)</sup>.

The exact etiology of rhinophyma is not known. It is thought to be due to numerous factors like alcohol, *Demodex folliculorum* (facial mite), and *H. pylori*. Sunlight is believed to be a major triggering factor for rosacea. In our presentation, the patient had a history of working in sunlight for long durations. Foods which cause facial flushing such as alcohol, spicy food, coffee and tea may aggravate rosacea and make it more prominent. There are conflicting reports about the association between rhinophyma and alcohol abuse. But there is no statistical evidence to support the role of alcohol as an etiology for rhinophyma, as reported by Curier et al. <sup>(6)</sup>.

The main complaint in patients with rhinophyma is facial disfigurement. The bony and cartilaginous framework is not affected in most cases. Some patients complain of nasal obstruction, if the swelling is large. On the hand, vision may be disturbed as the mass is large and comes into the field of vision. Our patient's presentation was mainly facial disfigurement.

The treatment of Rhinophyma is mainly surgical. The non-surgical treatment such as retinoids and topical antibiotics is limited to rosacea <sup>(1)</sup>. There is a wide range of surgical treatments available at present, such as scalpel and razor blade excision, cryosurgery, electrosurgery, resection with heated knives and



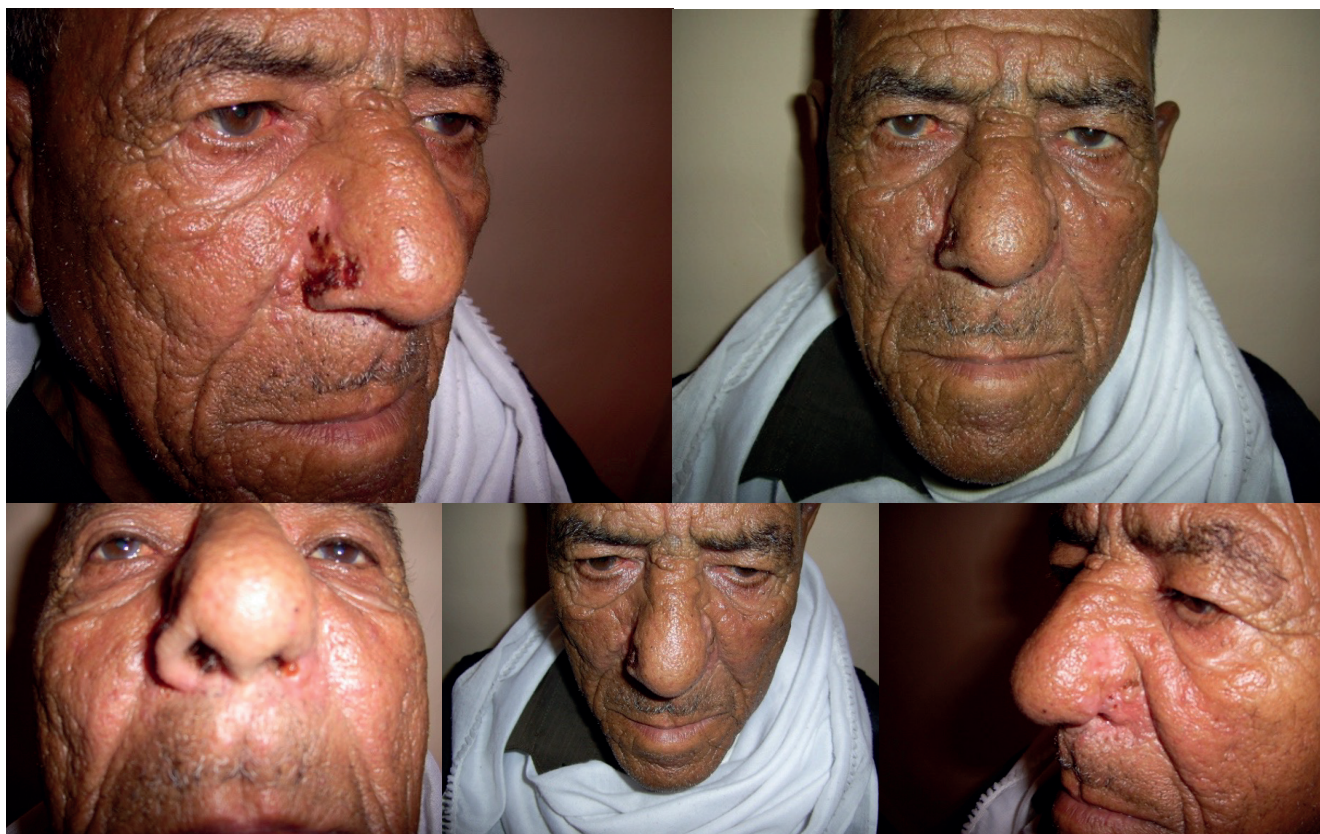

Figure 2. The complete healing process of raw area by two weeks postoperatively without any skin grafting.

loops, dermabrasion, CO<sub>2</sub> laser, and Argon laser<sup>(5)</sup>. Kaushik et al., described a technique of rhinophyma treatment by microdebrider and Floseal<sup>(7)</sup>.

The choice of surgical methods should be based on the extent of the disease, expense, availability, operating time, user experience and general health status of the patient<sup>(1)</sup>.

Surgical treatment of rhinophyma started in 1845 using excisions with primary or secondary closure. Skin grafting was added to this in 1912<sup>(8)</sup>. However, Fisher demonstrated that skin grafting had no additional advantage. This is in agreement with our concept.

Eisen, in 1986, described the use of a Shaw knife for rhinophyma. This scalpel heats from 110 to 270 degrees Celsius. It provides a narrower zone of tissue destruction than electrocautery<sup>(10)</sup>. Vural et al., in 2010, described in a review seven patients who underwent treatment of rhinophyma with a shaw knife and showed excellent outcomes<sup>(11)</sup>. Greenbaun compared the results of electrosurgery and CO<sub>2</sub> laser in rhinophyma surgery and concluded that both gave equivalent cosmetic result. He also stated that the use of CO<sub>2</sub> laser is more time consuming and 15 to 20 times more expensive than electrosurgery<sup>(12)</sup>. El-Azhary used the CO<sub>2</sub> laser in minor and moderate cases<sup>(13)</sup>. Madan et al., reported a review of 124 patients who underwent treatment

with Carbon dioxide laser for rhinophyma and concluded it to be an effective and durable treatment for rhinophyma<sup>(14)</sup>. Wenig, in 1983, used an Argon laser for rhinophyma and advocated its use for hemostasis and for telangiectasias<sup>(15)</sup>. The YAG laser was first used in rhinophyma by Wenig in 1993. He used it in six patients and found equally good cosmetic results with a shorter healing time compared to the CO<sub>2</sub> laser. This is thought to be due to the shorter thermal damage zone compared to the CO<sub>2</sub> treatment. The use of the diode laser was reported by Apikian et al., in 2007. They reported 5 cases of mild to moderate rhinophyma who were treated with a diode laser<sup>(6)</sup>. In addition, Bhandary and Baht confirmed the same concept in 2011<sup>(1)</sup>.

Although the diagnosis of rhinophyma is mainly clinical, still, histopathological examination of the specimen is essential to rule out the presence of co-existing pathology. The deformity due to the rhinophyma may hinder the examination of the nasal skin, hence malignancies may go unnoticed. Acker et al. reported a 3% to 10% incidence of basal cell carcinoma in patients with rhinophyma<sup>(16)</sup>. Histopathological examination of the excised specimen in our patient showed rhinophyma, without evidence of malignancy.

### Acknowledgments

To the patient who gave me the agreement to publish his case

report.

### Funding

No funding was received to present this work.

### Authorship contribution

KMB is the contributing author who is responsible for all aspects of this article.

### Ethics approval

The article was approved by the organization, as well as the statistical department at AL-Thawra central teaching hospital-

ALbyeda city, Libya.

### Consent for publication

The patient gave informed consent regarding the management modality as well as the publication of his personal photos.

### Availability of data and material

Not applicable.

### Conflict of interest

None.

## References

1. Bhandary SK, Bhat VS. Rhinophyma - Excision by Diode Laser. *WAENT*, 2011, 4 (1) 1-14.
2. Roberts JO, Ward CM. Rhinophyma. *J R Soc Med*. 1985; 78(8): 678-681.
3. Wiemer DR. Rhinophyma. *Clin Plast Surg*. 1987;14(2):357-365.
4. Rebora A. Rosacea. *J Invest Dermatol*. 1987;88(3 Suppl):56s-60s.
5. Sadick H, Goepel B, Bersch C, et al. Rhinophyma: diagnosis and treatment options for a disfiguring tumor of the nose. *Ann Plast Surg*. 2008;61(1):114-120.
6. Curnier A, Choudhary S. Triple approach to rhinophyma. *Ann Plast Surg*. 2002;49(2): 211-214.
7. Kaushik V, Tahery J, Malik TH, Jones PH. New surgical adjuncts in the treatment of rhinophyma: the microdebrider and FloSeal. *J Laryngol Otol*. 2003;117(7):551-552.
8. Apikian M, Goodman GJ, Roberts S. Management of mild to moderate rhinophyma with a 1,450-nm diode laser: report of five patients. *Dermatol Surg*. 2007 Jul;33(7):847-850.
9. Fisher WJ. Rhinophyma: its surgical treatment. *Plast Reconstr Surg*. 1970 May;45(5): 466-470.
10. Eisen RF, Katz AE, Bohigian RK, Grande DJ. Surgical treatment of rhinophyma with the Shaw scalpel. *Arch Dermatol*. 1986;122(3):307-309.
11. Vural E, Royer MC, Kokoska MS. Sculpting resection of rhinophyma using the Shaw scalpel. *Arch Facial Plast Surg*. 2009;11(4):263-266.
12. Greenbaum SS, Krull EA, Watnick K. Comparison of CO2 laser and electrosurgery in the treatment of rhinophyma. *J Am Acad Dermatol*. 1988;18(2 Pt 1):363-368.
13. el-Azhary RA, Roenigk RK, Wang TD. Spectrum of results after treatment of rhinophyma with the carbon dioxide laser. *Mayo Clin Proc*. 1991;66(9):899-905.
14. Madan V, Ferguson JE, August PJ. Carbon dioxide laser treatment of rhinophyma: a review of 124 patients. *Br J Dermatol*. 2009 Oct;161(4):814-818.
15. Wenig BL, Weingarten RT. Excision of rhinophyma with Nd:YAG laser: a new technique. *Laryngoscope*. 1993 Jan;103(1 Pt 1): 101-103.
16. Acker DW, Helwig EB. Rhinophyma with carcinoma. *Arch Dermatol*. 1967 Mar;95(3): 250-254.

Khalid Mohamed Bofares  
Omar Almoukhtar University  
Elbyda  
Libya

E-mail: bofaresstat2012@yahoo.com